

## Multiple cases of feline dermatophytosis due to *Microsporum canis* transmitted to their owners

Farzad Katirae<sup>1\*</sup>, Javad Asharafi Helan<sup>1</sup>, Fardis Teifoori<sup>2</sup>

1-Department of Pathobiology, Faculty of Veterinary Medicine, University of Tabriz, Tabriz, Iran

2-Department of Immunology, Microbiology and Parasitology, Faculty of Pharmacy and Laboratory of Parasitology and Allergy, Lascaray Research Centre, University of the Basque Country, Vitoria, Spain

\*Corresponding author: [f.katirae@tabrizu.ac.ir](mailto:f.katirae@tabrizu.ac.ir)

(Received 23 August 2015; Accepted 5 July 2016)

### Summary

Zoophilic dermatophytes such as *Microsporum canis* are significant causal agents of ringworm in many areas of the world. The present study was designed to investigate epidemiological factors of *Microsporum canis* that transmitted from cats to their owners diagnosed with dermatophytosis. From January 2011 to January 2014, thirty cats and their owners with dermatophytosis lesions were examined. Direct examination carried out on hair and skin samples with 10%KOH and Lacto phenol blue. Fungal cultures were performed by Sabouraud's dextrose agar with chloramphenicol (0.5%) and actidione. Colonies were identified on their morphology and microscopic characteristics. Lesions in cats were single or multiple in different types, mostly localized on the face and head. However, they were found on any part of the body, including the distal part of the legs and the tail. Among 30 cats with dermatophytosis 53.3% were female and 47.7% were male. Their age ranged from 2 months to 7 years. The affected sites were head and face (n=20), legs and trunk (n=13). The exposed sites were those most often affected. Single and multiple eruptions were observed in 20 and 10 cats, respectively. In the owners, the disease type was *tinea corporis* in 20 and *tinea capitis* in 3 patients. No combination of *tinea corporis* and *tinea capitis* was observed. In most cases the lesions were moderate to severe. No resistance to antifungal treatment was found. Apart from direct contact with infected cats, no predisposing factor was found in this study.

**Key words:** Dermatophytosis, Cat, Human.

### Introduction

Dermatophytes are usually the most frequent causes of dermatological problems in domestic animals (Betancourt et al., 2009; da Costa et al., 2013). Dermatophytosis is a common infection that involves keratinized tissues including skin, nails and hair with inflammatory reaction in the host,

characterized by multifocal alopecia, scaling and circular lesions. Animals serve as reservoirs of the zoophilic dermatophytes, and their infections have considerable zoonotic importance (da Costa et al., 2013; Rezaei-Matehkolaei et al., 2012; Hermoso de Mendoza et al., 2010; Cabañes, 2000).

Zoophilic species such as *Microsporum canis*, *Trichophyton mentagrophytes* var. *mentagrophytes* and *T. verrucosum* are significant causal agents of human ringworm in many areas of the world. The incidence of dermatophytosis varies according to climate and natural reservoirs (Cabañes, 2000). However, the pattern of the species of dermatophytes involved in dermatophytosis may be different in similar geographical conditions, both in humans and animals.

Epidemiological studies on the isolation of dermatophytes from dogs and cats with suspected lesions of dermatophytosis have been reported by various researchers (Lewis et al., 1991; Sparkes et al., 1993).

Lesions in cats appear primarily on the face and paws. In cats with suspected lesions of dermatophytosis the prevalence of dermatophytes is usually higher than in dogs, and it is usually more than 20% (Sparkes et al., 1993; Lewis et al., 1991). Cats are accepted as the principal reservoir for *M. canis*. This species is the most common dermatophyte isolated from cats, with percentages of isolation higher than 90% from animals with suspected lesions of dermatophytosis (Sakae et al., 2011; DeBoer et al., 2003). Other dermatophytes less commonly isolated from cats are *T. mentagrophytes* and *M. gypseum*. These three species comprise approximately 98% of the isolated dermatophytes from cats in the above cited epidemiological studies (Sparkes et al., 1993).

The present study was designed to investigate the prevalence of *M. canis* that transmitted from cats cohabiting with owners to their owners diagnosed with

dermatophytosis. In addition, this study evaluated the age, sex, breed, habitat and season as potential risk factors associated with the isolation of *M. canis* from cat owners that involved with dermatophytosis.

## Materials and Methods

From January 2010 to January 2013, thirty cases of cats and their owners with dermatophytosis lesions were examined. All cats included in the study were from the Tehran and East Azerbaijan providences (Iran) and were examined and sampled at private veterinary facilities, or at the Faculty of Veterinary Medicine (University of Tabriz). Animals lived in urban areas (center of a large city) where they were not allowed to range freely. Some of these cats lived together.

At the time of examination and sampling, the animals were evaluated for any predisposing factor for dermatophytosis. Owners of cats selected for sampling had dermatophytic lesions. They were questioned on their own and their family members history of dermatophytosis diagnosed by fungal culture. Epidemiological data were collected, as the age, sex, breed and habitat of the animals were recorded. In order to evaluate seasonal trends in dermatophyte infections, the sampling period was recorded. Also fifteen human infected with *M. canis* that referred to medical laboratories were questioned for owning cats and their dermatophytic lesions.

Hair and skin samples were collected from cases using the scraping technique. After specimen collection, the scraped skin and hair samples were placed in original

package and transported as soon as possible to the laboratory for direct examination and fungal culture. Direct examination carried out with 10% KOH and Lacto phenol blue. Fungal cultures were performed by Sabouraud's dextrose agar with chloramphenicol (0.5%) and actidione and incubated at 25°C for 15 days. Colonies grown in the medium were identified based on their morphology and microscopic characteristic of the hyphae, macroconidia and microconidia (de Hoog et al., 2000, Rezaei-Matehkolaei et al., 2012).

## Results

The typical clinical sign of *M. canis* infection in cats is ringworm or regular and circular alopecia, with hair fracture, desquamation, sometimes an erythematous margin and central healing. In this study we observed various types of presentation in cats as some lesions to be quite small but some have a diameter of 5-7 cm.

Lesions were single or multiple, mostly localized on the face and head. However they were found on any part of the body, including the distal parts of the legs and the tail. Young cats, in particular, displayed lesions localized to the bridge of the nose at first extending to the temples, the external side of the pinnae and auricular margins. In some cases multiple lesions grown together all over the body. All cats have variable pruritus without fever and loss appetite.

Frequently, in clarified samples with KOH and LCB arthrospores are seen surrounding and within the hair shaft. In some cases fungal hyphae and arthrospores in scraped skin were seen. A flat, white,

fluffy, spreading colony developed within 7 to 15 days. A characteristic deep yellow pigment may be observed on the reverse side of a colony on Sabouraud's dextrose agar or DTM. On DTM, the media should change from amber to red, concurrent with growth. Observation of a Lacto phenol Blue mount will reveal septate hyphae and numerous, fusiform, thick-walled macroconidia that usually contain more than six compartments. A few club-shaped, smooth-walled microconidia also may be present, as well as round-shaped chlamydoconidia. Among *M. canis* colonies isolated from cats, 90% have good sporulation and produce abundant macroconidia whereas 10% of isolates was poor in macroconidia production. On the other hand, 21% *M. canis* isolated from human cases in this study were poor in sporulation on mycological media.

In this study cats and their owners with dermatophytic lesions were contemporarily examined. Among 30 cats with dermatophytosis, 53.3% were female and 47.7% were male. They ranged in age from 2 months to 7 years. The affected sites were the head and face (n=20), leg and trunk (n=13); exposed sites were those most often affected (Fig 1). Single and multiple eruptions were observed in 20 and 10 cats, respectively. In the owners, the disease type was *tinea corporis* in 20 patients, and *tinea capitis* in 3 cases (all of them were child men) (Fig 2). No combination of *tinea corporis* and *tinea capitis* were observed. The disease showed familial onset in 2 patients, including 2 sibling pairs (Table 1). In most of cases, the lesions were moderate to severely inflammatory. There were 8

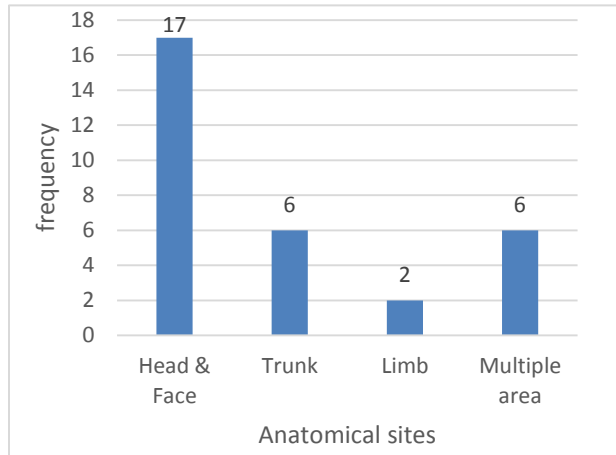
patients that their lesions were limited with low inflammatory reaction. The human patients were treated with topical antifungal agents, oral Itraconazole or terbinafine for 2-14 weeks, combined with topical antifungal therapy. However, two patients had recurrent infection after discontinuation of antifungal usage. These patients were treated with combination therapy. No resistance to

antifungal treatment was found, however one patient developed dermatophytic lesions after ketoconazole prescription. After shifting the treatment from antifungal to Itraconazole agent, the lesions were disappeared. We did not find any predisposing factors except encountering and dealing with infected cats (Table 1).

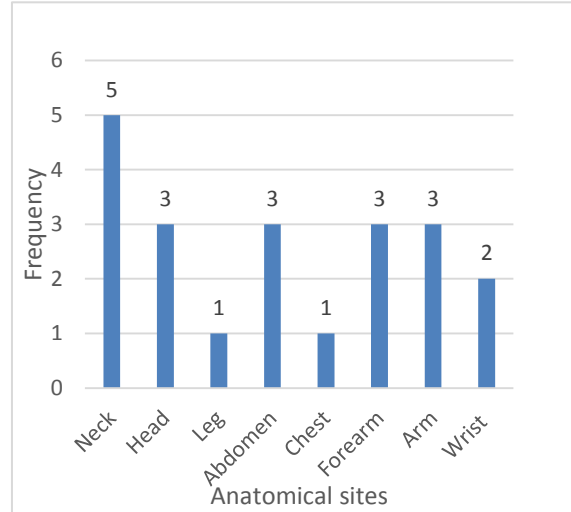
**Table1.** Full description of 30 cases of feline dermatophytosis transmitted to human.

No	Sex/age of cats	Time lesion based on season	Site of infection in cat	Sex/ age of the owner	Owner site of infection	Habitat	Referred to	Treatment for cats	Other
1	F/3m	Winter	Chin	F/33	Arm	In	Animal clinic	Griseofulvin	Common owner
2	F/3m	Winter	Nose and mouth	F/33	Arm	In	Animal clinic	Griseofulvin	
3	M/1y	Winter	Abdomen	F/33	Arm	In	Animal clinic	Griseofulvin	
4	M/3m	Fall	Nose	F/56	Face	In /out	Animal clinic	Ketoconazole	Common owner
5	M/3m	Fall	Surround of Eye	F/56	Face	In /out	Animal clinic	Ketoconazole	
6	F/1y	Winter	Leg and paw	M/12	Neck	In	Animal clinic	Itraconazole	
7	F/2m	Spring	Auxiliary region	F/10	Wrist	In /out	Animal clinic	Griseofulvin	
8	F/6m	Spring	Mouth	M/7	Head	In /out	Animal clinic	Terbinafine	
9	M/8m	Spring	Chin	F/45	Neck	In	Clinical lab	Griseofulvin	
10	M/1y	Summer	Multiple parts	M/66	Abdomen	Out	Clinical lab	Itraconazole	
11	M/4y	Summer	Whisker	F/34	Leg	In	Animal clinic	Itraconazole	
12	M/3m	Fall	Multiple parts	F/25	Wrist	In	Animal clinic	Ketoconazole	
13	F/11m	Fall	Abdomen, leg	F/37	Arm, neck	In	Clinical lab	Griseofulvin	Sister s owner involved
14	F/2y	Winter	Ear and temple	F/50	Face	In	Clinical lab	Griseofulvin	
15	F/7y	Winter	Auricular margins	F/55	Chest	In	Animal clinic	Ketoconazole	
16	F/2m	Winter	Whisker	M/9	Head	Out	Animal clinic	Itraconazole	
17	F/1y	Fall	Auricular margins	M/12	Forearm	In	Clinical lab	Griseofulvin	
18	F/3y	Fall	Auxiliary region	F/19	Arm	In	Clinical lab	Terbinafine	
19	M/3y	Fall	Head	F/33	Nose	In	Clinical lab	Griseofulvin	
20	F/10m	Winter	Multiple parts	F/50	Neck	In /out	Animal clinic	Itraconazole	Common owner
21	M/3y	Winter	Multiple parts	F/50	Neck	In /out	Animal clinic	Itraconazole	
22	M/5y	Winter	Whisker	F/50	Neck	In /out	Animal clinic	Itraconazole	
23	M/5m	Winter	Multiple parts	F/50	Neck	In /out	Animal clinic	Itraconazole	
24	M/1y	Fall	Whisker	F/22	Abdomen	Out	Clinical lab	Ketocpnazole	
25	M/2y	Winter	Back and tail	M/10	Forearm	In	Animal clinic	Griseofulvin	
26	F/7m	Winter	Mouth and chin	M/11	Head	In /out	Clinical lab	Ketoconazole	
27	F/2y	Winter	Chin	F/30	Neck	In /out	Animal clinic	Itraconazole	
28	M/1y	Winter	Head	F/15	Abdomen	In /out	Animal clinic	Griseofulvin	
29	F/9m	Spring	Multiple parts	F/40	Forearm	In /out	Animal clinic	Griseofulvin	
30	F/6y	Spring	Abdomen	F/40	Forearm	In /out	Animal clinic	Griseofulvin	Common owner

In: indoor, out: outdoor



**Fig 1.** Frequency of infected anatomical sites in cats with dermatophytosis.



**Fig 2.** Frequency of infected anatomical site in cat owners.

## Discussion

*Microsporum canis*, as zoophilic dermatophyte was responded as the dominant agent of *tinea corporis* in some European countries and currently is the most common *Microsporum* species causing dermatophytosis in Iran. In the studies carried out in Greece and Italy, *M. canis* was mentioned as the prevailing agent of *tinea faciei*. In addition, it is found to be the most common etiologic agents of *tinea capitis* in Iran (Rezaei-Matehkolaei et al., 2012).

Despite extensive development in medical science, dermatophytes are the prevalent skin diseases that encounter any age group, sex and profession and cause enormous economic damages. *M. canis* can cause highly inflammatory *tinea corporis*, *tinea faciae* and *tinea capitis* in human (Sharma et al., 2007). In cases of such human mycosis, it is important to identify certainly the precise etiological agent and to examine pets as the possible source of infection. Identifying pets as the source of

infection of people can help preventing reoccurrence of dermatophytosis or new infections, especially in children, by adequately treating affected pets cleaning and their surrounding environments. These results clearly indicate that cats should be considered as a major source of pathogenic dermatophytes for humans especially in children, elderly and animals retentive (Cafarchia et al., 2006; Cafarchia et al., 2013). The result of this study showed that most cases were females and the underlying reason is perhaps the greater contact of females with the contaminating cats in their living sites. The female have more interest for keeping animals such as cats in their living sites. While gender differences in infection rate whit *M. canis* are controversial, some studies revealed that girls are affected more frequently than boys (Aly, 1999; Skerlev and Miklić, 2010).

From the age point of view the distribution of cases was widespread as of each age group were involved in the disease,

however most infected cats belonged to the age group less than year one. This is similar to the results of other studies (Skerlev and Miklić, 2010). The reason for less infection in higher ages can be justified as immunological reasons and skin conditions.

The transmission of *M. canis* occurs via infective arthrospores present on the hair coats of dogs and cats or in the environment. Humans may be infected, and *M. canis* has become the most frequently encountered zoonotic dermatophyte in urban areas. The prevalence of *M. canis* infections in humans differs from one country to another. In Iran, it is one of the most commonly dermatophytes isolated from *tinea capitis* and *tinea corporis* cases, in spite of the fact that, the number of dogs and cats kept as pets in our country is not very great (Havlickova et al., 2008). Asymptomatic animal carriers of *M. canis* especially cats are considered to be the critical factor in the epidemiology of the disease at 50% of human cases (Cafarchia et al., 2006). In conclusion, animals kept at home may have served as the infection source and the possibility of the transmission of this disease from pets such as cats to humans must be taken in to the account. Screening of domestic animals specially cats suspected to dermatophytosis and necessary treatments could help in the management of human dermatophytosis as a public health problem.

#### Acknowledgements

We thank all practitioners who collected samples for their valuable contribution.

#### References

- Aly R. (1999). Ecology, epidemiology and diagnosis of tinea capitis. *Pediatric Infectious Disease Journal*, 18, pp.180-185.
- Betancourt O., Salas V., Otarola A., Zaror L., Salas E. and Neumann J. (2009). *Microsporum canis* on dermatologically healthy cats in Temuco city, Chile. *Revista Iberoamericana de Micología*, 26(3), pp.206-210.
- Cabañes F. (2000). Dermatophytes in domestic animals. *Revista Iberoamericana de Micología*, 17<sup>th</sup> ed. pp.104-108.
- Cafarchia C., Gasser R. B., Figueredo L.A., Weigl S., Danesi P., Capelli G. and Otranto D. (2013). An improved molecular diagnostic assay for canine and feline dermatophytosis. *Medical Mycology*, 51(2), pp.136-43.
- Cafarchia C., Romito D., Capelli G., Guillot J. and Otranto D. (2006). Isolation of *Microsporum canis* from the hair coat of pet dogs and cats belonging to owners diagnosed with *M. canis tinea corporis*. *Veterinary Dermatology*, 17(5), pp.327-331.
- da Costa F.V., Farias M.R., Bier D., de Andrade C.P., de Castro L.A., da Silva S. C. and Ferreiro L. (2013). Genetic variability in *Microsporum canis* isolated from cats, dogs and humans in Brazil. *Mycoses*.
- de Hoog G., Guarro J., Gene J. and Figueras M. (2000). *Atlas of Clinical Fungi, Centraalbureau voor Schimmelcultures Utrecht, The Netherlands*.
- DeBoer D.J., Moriello K.A., Blum J.L. and Volk L.M. (2003). Effects of lufenuron

- treatment in cats on the establishment and course of *Microsporium canis* infection following exposure to infected cats. *Journal of the American Veterinary Medical Association*, 222(9), pp.1216-1220.
- Havlickova B., Czaika V.A. and Friedrich M. (2008). Epidemiological trends in skin mycoses worldwide. *Mycoses*, 51, pp.2-15.
- Hermoso de Mendoza M., Hermoso de Mendoza J., Alonso J.M., Rey J.M., Sanchez S., Martin R., Bermejo F., Cortes M., Benitez J., M. Garcia W. L. and Garcia-Sanchez A. (2010). A zoonotic ringworm outbreak caused by a dysgonic strain of *Microsporium canis* from stray cats. *Revista Iberoamericana de Micología*, 27(2), pp. 62-65.
- Lewis D., Foil C. and Hosgood G. (1991). Epidemiology and clinical features of dermatophytosis in dogs and cats at Louisiana State University: 1981-1990. *Veterinary Dermatology*, pp.53-58.
- Rezaei-Matehkolaei A., Makimura K., de Hoog G., S. Shidfar M., R. Satoh K., Najafzadeh M. J. and Mirhendi H. (2012). Multilocus differentiation of the related dermatophytes *Microsporium canis*, *Microsporium ferrugineum* and *Microsporium audouinii*. *Journal of Medical Microbiology*, 61(Pt 1), pp.57-63.
- Sakae H., Noguchi H., Ichinokawa Y. and Hiruma M. (2011). Analysis of 25 cases of *Microsporium canis* infection encountered at a dermatology clinic in Kumamoto during a recent 3-year period. *Medical Mycology Journal*, 52(2), pp.139-144.
- Sharma R., de Hoog S., Presber W. and Graser Y. (2007). A virulent genotype of *Microsporium canis* is responsible for the majority of human infections. *Journal of Medical Microbiology*, 56(Pt 10), pp.1377-1385.
- Skerlev M. and Miklič P. (2010). The changing face of *Microsporium* spp infections. *Clinics in Dermatology*, 28, pp.146-150.
- Sparkes A., Gruffydd-Jones T., Shaw S., Wright A. and Stokes C. (1993). Epidemiological and diagnostic features of canine and feline dermatophytosis in the United Kingdom from 1956 to 1991. *Veterinary Record*, 133, pp.57-61.