

## Investigating the prevalence of *Linguatula serrata* infection in herbivores as intermediate hosts and carnivores as final hosts in northwest Iran

Hadi Mardomi<sup>1</sup>, Mousa Tavassoli<sup>1\*</sup>, Nasser Hajipour<sup>2</sup>, Farnaz Malekifard<sup>1</sup>, Bijan Esmaeilnejad<sup>1</sup>

<sup>1</sup>Department of Pathobiology, Faculty of Veterinary Medicine, Urmia University, Urmia, Iran

<sup>2</sup>Department of Food Hygiene and Aquatic, Faculty of Veterinary Medicine, University of Tabriz, Tabriz, Iran

### Article type:

Original article

### Keywords:

*Linguatula serrata*  
Prevalence  
Wild animals  
Iran

### Article history:

Received:

July 11, 2024

Revised:

August 19, 2024

Accepted:

August 19, 2024

Available online:

September 22, 2024

### Abstract

Pentastomids are arthropod parasites that primarily infect canids and vulpids as definitive hosts, along with various herbivores serving as intermediate hosts. Understanding the prevalence of these infections is crucial for wildlife management and public health. The study aimed to assess the prevalence of pentastomid infections in wild animals in East Azerbaijan in northwest Iran, focusing on species lost due to road accidents, conflicts, or diseases. Samples were collected from the liver and mesenteric lymph nodes of herbivores and the nasal cavities of carnivores. The study included a variety of species (Golden Jackals, Common Foxes, Jungle Cats, Eurasian Lynx, Brown Bears, Honey Badgers, Red Deer, Persian Gazelles, Wild Goats, and Armenian Wild Sheep), and the samples were obtained from animals managed by the Environmental Protection Organization. The study included Golden Jackals, Common Foxes, Jungle Cats, Eurasian Lynx, Brown Bears, Honey Badgers, Red Deer, Persian Gazelles, Wild Goats, and Armenian Wild Sheep. However, the study found no infestation with larval or adult pentastomid stages in any of the 42 samples examined. Identifying the pathogens and understanding their life cycles in wildlife is essential for preventing disease outbreaks that could impact public health and domestic animals. However, the study faced limitations, including the unavailability of carcasses and difficulties in accessing protected areas, which may have affected the comprehensiveness of the findings.

### Introduction

*Linguatula serrata* is an aberrant arthropod with the class Pentastomida (1). The parasite is called the tongue worm because of its tongue-shaped appearance (2). These organisms are parasitic wormlike and mostly inhabit the upper respiratory system of vertebrates, including the nasal cavities,

turbinates, and occasionally the frontal sinuses. Dogs, foxes, cats, and other predatory animals are the definitive hosts for these parasites (3). These wild canids possess the capacity to serve as a reservoir for the transmission of infestations to a diverse array of mammals, including livestock, wildlife, domestic dogs, and potentially humans (as

\*Corresponding author: [m.tavassoli@um.ac.ir](mailto:m.tavassoli@um.ac.ir)

<https://doi.org/10.22034/jzd.2024.18538>

[https://jzd.tabrizu.ac.ir/article\\_18538.html](https://jzd.tabrizu.ac.ir/article_18538.html)

Cite this article: Mardomi H., Tavassoli M., Hajipour N., Malekifard F., and Esmaeilnejad B. Investigating the prevalence of *Linguatula serrata* infection in herbivores as intermediate hosts and carnivores as final hosts in northwest Iran. *Journal of Zoonotic Diseases*, 2025, 9 (2): 830-837.

Copyright© 2025, Published by the University of Tabriz.

This is an open-access article distributed under the terms of the Creative Commons Attribution 4.0 International (CC BY NC)



carriers of Halzou syndrome) (4). The eggs are expelled from the respiratory tract of the definitive host and pollute grazing areas and water sources. Upon ingestion by appropriate herbivorous animals, the infected eggs traverse to the mesenteric lymph nodes, liver, lungs, spleen, and occasionally, the eyes and other organs (5). Pathological lesions and symptoms are caused by parasites that penetrate an intermediate host. The manifestation of symptoms is contingent upon the affected organ. Infestation with this parasite leads to symptoms in the intermediate hosts such as emaciation, pale mucosal membranes, ascites, inflammation of the peritoneum, and adhesion of the intestines. Significant symptoms induced by the disease in sheep encompass hyperplasia of pulmonary lymphatic tissue and pneumonia (6). *L. serrata* has significant public health implications, as both the adult and nymphal stages can infect humans (7). Humans can become infected with *Linguatula serrata* through two primary routes: ingestion of *L. serrata* nymphs, which leads to a condition known as nasopharyngeal linguatulosis or Halzou syndrome, and ingestion of infective eggs that develop in internal organs, resulting in visceral linguatulosis. A significant number of human illnesses exhibit no symptoms, with the disease being discovered incidentally during normal medical consultations or post-mortem examinations (8). Manifestations comprise ocular involvement, loss of vision, and hepatic granuloma. The combination of clinical indications results in a syndrome called type I hypersensitivity, which is also referred to as Marrara or Halazou syndrome (9). In cases of severe infestations caused by *L. serrata*, death may result from subsequent septicemia, pneumonia, or severe enterocolitis (10). The prevalence of *L. serrata* has been studied in various animals in Iran, including dogs, sheep, goats, camels, and cattle. There are also some reports of human linguatuliasis in Iran (11). Clinical signs associated with infestations in intermediate hosts have not yet been described carefully (12). This parasite has also been reported in humans from

different regions of Iran (13-17). Numerous studies have investigated the prevalence of *L. serrata* in various animals, including dogs (3, 18), camels (19), buffaloes (20), as well as sheep and goats (21-23), goats (24) and goats (25). Determining the prevalence rate of *L. serrata* adults and nymphs in wild animals in the northwest of Iran was the objective of this study. This study is important due to the diversity of carnivores and ruminants in the northwest of Iran and only one report of *L. serrata* in Iran so there is a lack of data on *L. serrata* prevalence in wild animals in Iran.

## Materials and methods

### Wildlife host

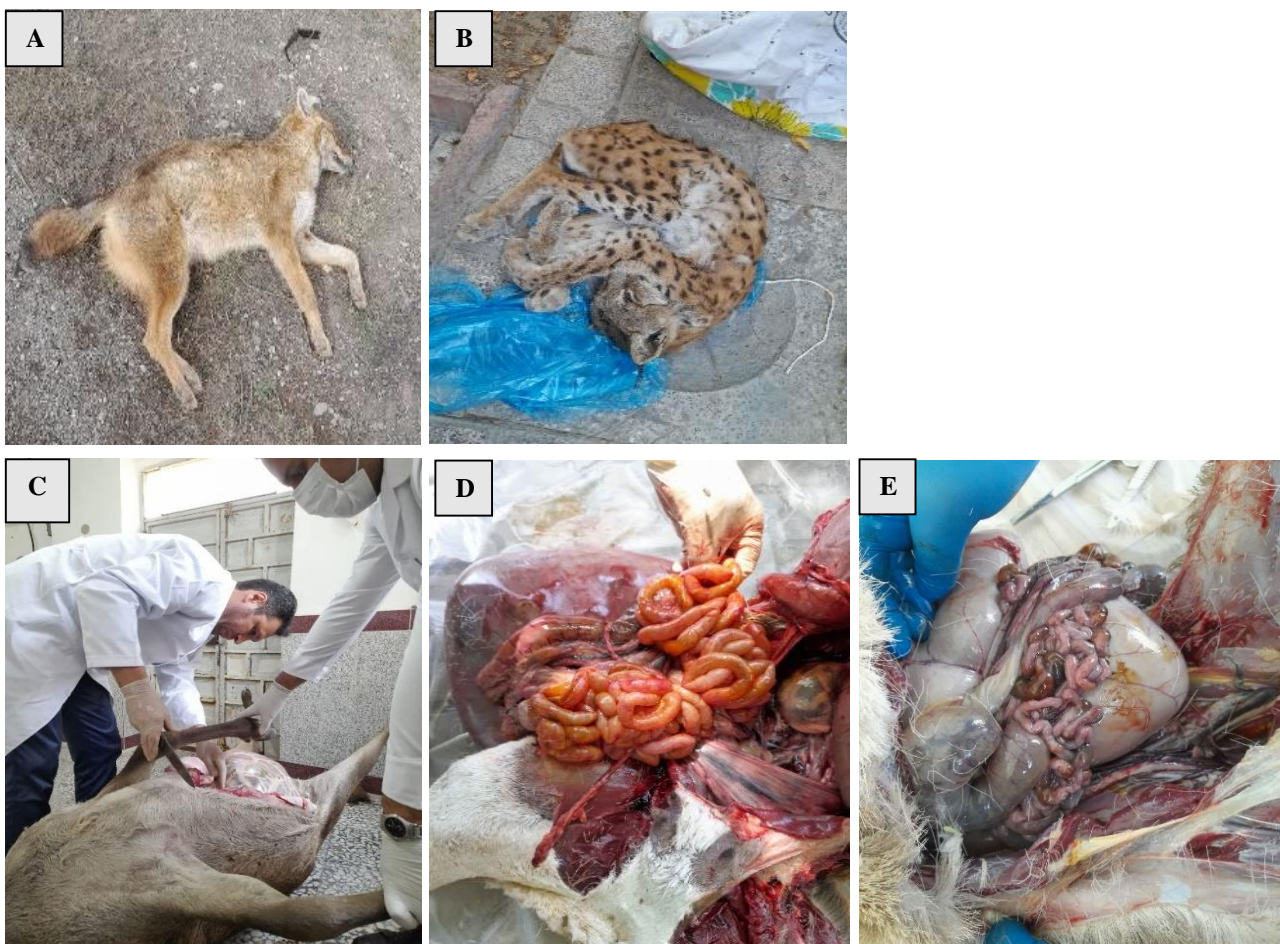The study was conducted in areas of northwest Iran, including Arasbaran National Park and Arasbaran Protected Area, which cover approximately 85,798 hectares and are influenced by the Caspian ecotone, as well as regions adjacent to the Aras River. Additionally, it included Kiamaki Protected Area and Kamtal National Park, spanning about 96,971 hectares, characterized by a Mediterranean climate. The Sahand and Kaghazkonan Protected Areas, with an area of approximately 115,543 hectares, are noted for their high diversity of plant and animal species. Wildlife samples were collected over two years, from March 2022 to February 2024, totaling 42 samples across 8 genera and species of intermediate and final hosts. In the collection of the carcasses, there was no involvement of the collector and the carcasses were due to an accident or death due to disease or a power struggle during mating. Figure 1 shows the distribution of species in different collected points. Carnivorous species of Iranian wildlife, including the common jackal, common fox, Eurasian lynx, forest cat, honey badger, and brown bear, serve as definitive hosts for *Linguatula serrata*. Additionally, herbivorous species from the order Artiodactyla, specifically from the families Bovidae and Cervidae, such as red deer, wild goat, Armenian wild sheep, and Iranian gazelle, act as intermediate hosts. Samples were collected and analyzed from these species.

Following the study, carcasses were either left in their original locations in compliance with ethical standards or provided to the environmental organization for use in a natural history museum. This revision improves the structure and flow while maintaining the essential information.

#### *Parasite collection*

The skull of the hunter species was cut in half using a knife and a hammer. During the sample collection process, care was taken to fragment the skull with minimal damage to surrounding tissues. This technique allows the skull to be fractured while preserving any tongue parasites that may be present. The use of alternative methods can interfere with

the investigation and observation of these parasites. In addition, this approach facilitates the visualization of both the right and left nasal cavities and allows the detection of any lingual parasites. For better diagnosis, the samples were referred to the laboratory and they were washed with a gentle stream of water and a 300 sieve. For herbivores, the liver and mesenteric lymph nodes were harvested postmortem and subsequently immersed in lukewarm water following a transverse incision. The lukewarm water relaxes the parasite and the use of a revision loop increases readability while preserving the essential details of the original text (Figures 1 and 2).



**Fig. 1.** A: A common fox that died in a road accident. B: Losses of Eurasian lynx due to conflict. C, D, and E: Mesenteric lymph nodes and liver tissue were collected from intermediate hosts.

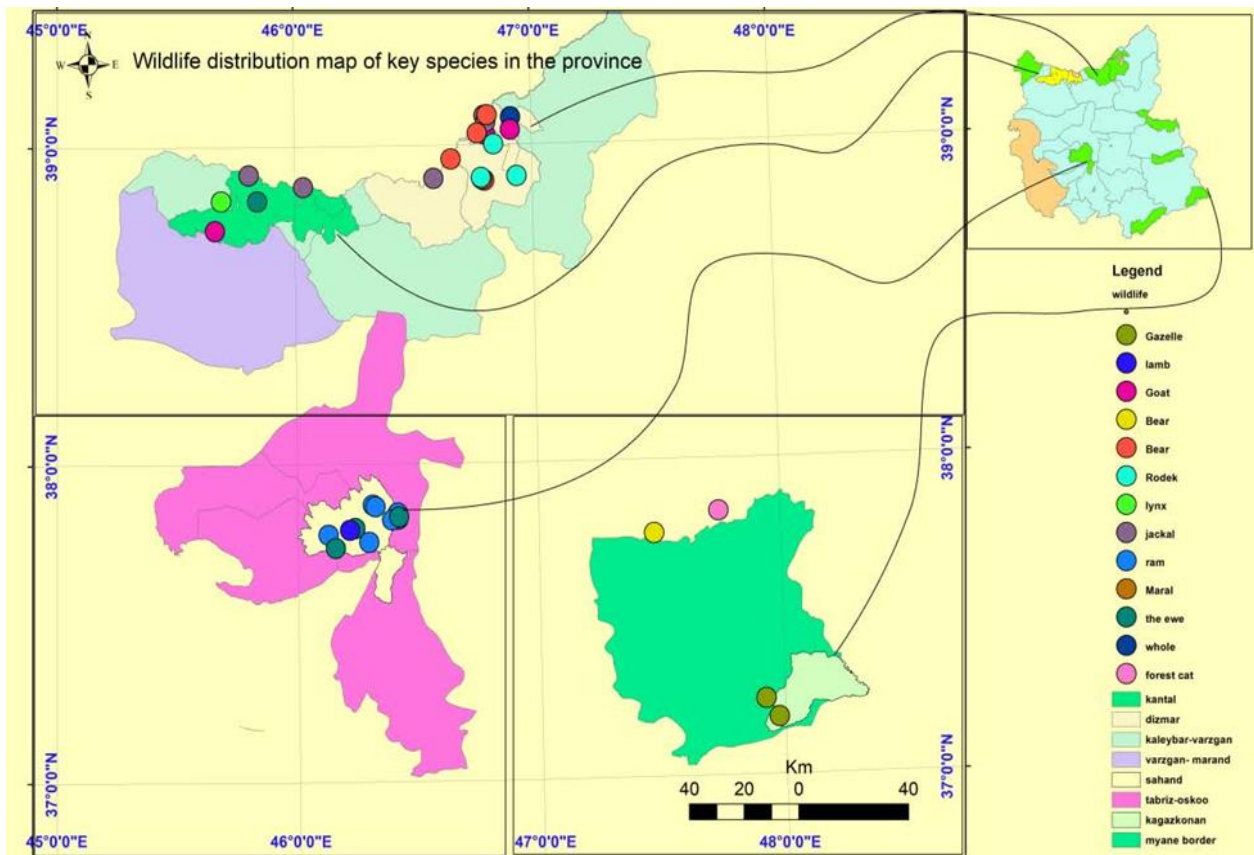


Fig. 2. Distribution of species in different collected points.

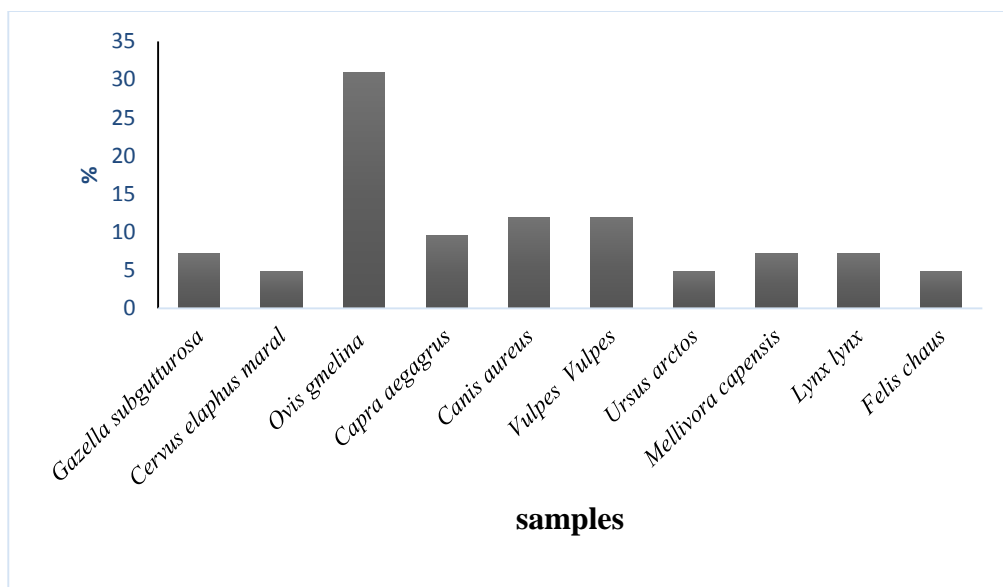


Fig. 3. Distribution of Wildlife samples examined for *Linguatula serrata* infestation in Northwest Iran.

## Results

In the present study, several potential intermediate and definitive hosts (n = 42), including Golden Jackal (*Canis aureus*; 11.9%; n = 5), Common Fox (*Vulpes Vulpes*; 11.9%; n = 3), Jungle Cat (*Felis chaus*; 4.76%; n = 2), Eurasian Lynx (*Lynx lynx*, 7.14%; n = 3), Brown Bear (*Ursus arctos*, 4.76%; n = 2), Honey Badger (*Mellivora capensis*, 7.14%; n = 3), Red Deer (*Cervus elaphus*, 4.76%; n = 2), Persian Gazelle (*Gazella subgutturosa*, 7.4%; n = 3), Wild Goat (*Capra aegagrus*, 9.52%; n = 4) and Armenian Wild Sheep (*Ovis gmelina*, 30.95%; n = 13), from the protected areas of northwest Iran were examined for infestation of *L. serrata* (Figure 3). The samples were collected from the areas under the management of the Environmental Protection Organization, where they were lost due to road accidents or mating conflicts and diseases. Neither intermediate hosts nor final hosts had any infestation with larval and adult stages of *L. serrata*, respectively. This negative result can be justified by the following factors: With only 42 animals examined across eight species, the study might have lacked sufficient power to detect *L. serrata*, and a larger sample size would have increased the confidence in the negative findings. A two-year sampling period might not be enough to capture seasonal variations in *L. serrata* prevalence, potentially leading to underestimation. Relying solely on carcasses from accidents, diseases, or predator interactions could skew the results. Future studies should aim to increase the sample size, both in terms of the total number of animals and the number of species represented. Conducting longitudinal studies over a more extended period could also help capture any seasonal or temporal variations in *L. serrata* prevalence.

## Discussion

Investigating the level of contamination in various intermediate and final hosts of *L. serrata*, as well as its hosts in wildlife species, can increase our understanding of this parasite's biology and pathogenesis and aid in future planning to control

it. This study was conducted on 42 samples of 8 species in the wildlife of northwest Iran and is the first serious step to identify *Linguatula* species in the wildlife of Iran. Results suggest that wildlife may be carriers of several pathogens that can be transmitted to domestic small ruminants and farmers (26). There are many reports of parasites in domestic animals. The infestation is also considered a food-borne disease in the Middle East and Asian countries (6, 27) due to its correlation with the ingestion of undercooked meat derived from parasitized domestic herbivores, particularly camels and cattle, as these animals hold significant dietary value in Islamic regions (28, 29). Recent studies conducted on domestic sheep have shown that the average positivity rate among tested animals is about 15% and 5% in Iran (7) and Turkey (30), respectively. Therefore, there is a possibility of its presence in the wild cycle. There are reports of the presence of the parasite in wildlife in Africa (31), Romania (32), Zimbabwe (33), and Italy (34). Thus far, a singular case study detailing the existence of said parasite has been documented in the southeastern region of Iran, particularly in Fars province and in the hydrangea species (*Hystrix indica*) within Iran's wildlife (35). Therefore, the potential for *Linguatula* to circulate in Iranian wildlife remains.

*Linguatula* infection was not observed in the recent study. A few potential environmental factors could contribute to the absence of *Linguatula* parasites in the study area:

- 1) Declining populations of the definitive hosts, such as canids and felids, may be a contributing factor in finding fewer *Linguatula* parasites. With fewer definitive hosts shedding eggs, there would be less environmental contamination and transmission to intermediate hosts (36).
- 2) The study area may not be suitable for *Linguatula* species due to environmental factors like temperature and humidity. Therefore, it is likely that in hotter and drier regions, any eggs released from infected definitive hosts may be rapidly

desiccated, preventing embryonation and transmission (37).

3) The sampling methods, which relied heavily on opportunistic collection of roadkill and damaged specimens, may have impacted the efficiency of finding *Linguatula* parasites in their hosts. Fresh, intact specimens may be needed to accurately determine the prevalence of the parasite (37).

4) The lack of *Linguatula* infestation in the sampled carnivores may indicate that these species do not commonly prey on the large herbivorous intermediate hosts that harbor the larval parasites. The carnivores likely feed more on smaller prey and scavenged food sources near human settlements, limiting their exposure to *Linguatula* and may provide inaccurate information about the host's parasite load (10). Hunting and other targeted sampling methods may be needed to more accurately assess parasite loads. Expanding the study area and sample size could help elucidate the relationship between predator and prey species relevant to *Linguatula* transmission. Examining a wider range of carnivore and herbivore species may reveal the presence of the parasite in the wildlife cycle. In general, aside from animals that are hunted and a few other cases, there is no available information on the parasite burden of the population (38). A suggested change in the study area is to make the relationship between the hunter and the prey more tangible and logical, and to increase the number of samples.

### Conclusion

In conclusion, this study did not detect *Linguatula* in the sampled carnivores. However, the negative findings highlight the need for further research using expanded geographic areas, larger sample sizes, and targeted sampling methods. This will help us better understand the role of wildlife in the parasite's life cycle in Iran. Investigating *Linguatula* prevalence across intermediate and definitive hosts in both domestic and wild animals can provide valuable insights into its biology and epidemiology.

### Acknowledgments

Thanks to the employees of the Environment Department of Northwest Iran for their assistance in sampling.

### Ethical approval

This study was carried out based on the legal license number 1401/400/3333, which was issued by the Environmental Protection Organization, Iran (1401/01/30), a reliable institution responsible for setting environmental standards and measures within the jurisdiction of the country.

### Conflict of interest

There is no conflict of interest in conducting this research.

### Reference

1. Hendrix CM. Diagnostic veterinary parasitology. 2nd ed. USA: Mosby; 1998.
2. Soulsby E JL. Helminths, arthropods and protozoa of domesticated animals. 7th ed. London: Baillière Tindall; 1982.
3. Meshgi B, Asgarian O. Prevalence of *Linguatula serrata* infestation in stray dogs of Shahrekord, Iran. J Vet Med. 2003; 50(9): 466-7. <https://doi.org/10.1046/j.0931-1793.2003.00705.x>
4. Shamsi S, McSpadden K, Baker S, Jenkins DJ. Occurrence of tongue worm, *Linguatula cf. serrata* (Pentastomida: Linguatulidae) in wild canids and livestock in south-eastern Australia. Int J Parasitol Parasites Wildl. 2017; 6(3): 271-7. <https://doi.org/10.1016/j.ijppaw.2017.08.008>
5. Attia MM, Ismael E, Saleh NM. A sensitive serodiagnostic tool for the detection of active infection of zoonotic visceral and nasopharyngeal linguatulososis. Vet World. 2019; 12(6): 883. <https://doi.org/10.14202/vetworld.2019.883-889>
6. Tabaripour R, Shokri A, Teshnizi SH, Fakhari M, Keighobadi M. Status of *Linguatula serrata* infection in livestock: a systematic review with meta-analysis in Iran. Parasite Epidemiol Control. 2019; 7: e00111. <https://doi.org/10.1016/j.parepi.2019.e00111>
7. Hajipour N, Tavassoli M. Prevalence and associated risk factors of *Linguatula serrata* infection in definitive and intermediate hosts in Iran and other countries: a systematic review. Vet Parasitol Reg Stud Reports. 2019; 16:

100288.  
<https://doi.org/10.1016/j.vprsr.2019.100288>
8. Hajipour N, Ketzis J, Esmailnejad B. Pathological characteristics of *Linguatula serrata* (aberrant arthropod) infestation in sheep and factors associated with prevalence in Iran. *Prev Vet Med.* 2019; 172: 104781. <https://doi.org/10.1016/j.prevetmed.2019.104781>
  9. Khalil GM, Schacher JF. *Linguatula serrata* in relation to halzoun and the marrara syndrome. *Am J Trop Med Hyg.* 1965; 14(5): 736-46. <https://doi.org/10.4269/ajtmh.1965.14.736>
  10. Gharekhan J, Esmailnejad B, Brahmata R, Sohrabei A. Prevalence of *Linguatula serrata* infection in domestic ruminants in west part of Iran: Risk factors and public health implications. *Istanbul Univ Vet Fak Derg.* 2017; 43(1): 28-31. <https://doi.org/10.16988/iuvfd.266125>
  11. Bajwa HUR, Khan MK, Abbas Z, Riaz R, Rehman Tu, Abbas RZ, et al. Nanoparticles: Synthesis and their role as potential drug candidates for the treatment of parasitic diseases. *Life (Basel).* 2022; 12(5): 750. <https://doi.org/10.3390/life12050750>
  12. Mehlhorn H. *Encyclopedia of Parasitology.* 3rd ed. Verlag Berlin Heidelberg: Springer; 2008. <https://doi.org/10.1007/978-3-540-48996-2>
  13. Maleky F. A case report of *Linguatula serrata* in human throat from Tehran, central Iran. *Indian J Med Sci.* 2001; 55(8): 439-41.
  14. Mohammadi GA, Mobedi I, Ariaiepour M, Pourmohammadi Z, Bidaki MZ. A case report of nasopharyngeal linguatuliasis in Tehran, Iran and characterization of the isolated *Linguatula serrata*. *Iran J Parasitol.* 2008; 3(1): 53-5.
  15. Montazeri A, Jamali R, Kazemi A, editors. Two case reports of *Linguatula serrata* (Halazoun syndrome) in human. Tabriz, Iran Second National Congress of Parasitic Diseases Tehran, Iran P; 1997.
  16. Siavashi MR, Assmar M, Vatankhah A. Nasopharyngeal pentastomiasis [Halzoun]: report of 3 cases. *Iran J Med Sci.* 2002; 27: 191-2.
  17. Sadjjadi S, Ardehali S, Shojaei A. A case report of *Linguatula serrata* in human pharynx from Shiraz, Southern Iran. *Med J Islam Repub Iran.* 1998;12(2):193-4. <http://mjiri.iums.ac.ir/article-1-1032-en.html>
  18. Rezaei F, Tavassoli M, Javdani M, editors. Prevalence and morphological characterizations of *Linguatula serrata* nymphs in camels in Isfahan Province, Iran. *Vet Res Forum.* 2012; 3(1): 61-5.
  19. Oryan A, Sadjjadi S, Mehrabani D, Rezaei M. The status of *Linguatula serrata* infection of stray dogs in Shiraz, Iran. *Comp Clin Path.* 2008;17:55-60. <https://doi.org/10.1007/s00580-007-0707-x>
  20. Tajik H, Tavassoli M, Javadi S, Bagheban H. The prevalence rate of *Linguatula serrata* nymphs in Iranian river buffaloes. *Asian J Anim Vet Adv.* 2008; 3: 174-8. <https://doi.org/10.3923/ajava.2008.174.178>
  21. Esmail Nia K, Hadizadeh Moalem S, Derakhshanfar A, Motamedi GH. A study on the prevalence of *Linguatula serrata* infestation in small ruminants of Mazandaran province in Babol abattoir. *Pajouhesh Sazandegi.* 2000; 45: 94-5.
  22. Razavi S, Shekarforoush S, Izadi M. Prevalence of *Linguatula serrata* nymphs in goats in Shiraz, Iran. *Small Rumin Res.* 2004; 54(3): 213-7. <https://doi.org/10.1016/j.smallrumres.2003.11.013>
  23. Shekarforoush SS, Arzani P. The prevalence rate of *Linguatula serrata* nymphs in the liver of sheep, goat and cattle in Shahre-Kord. *Iran J Vet Res.* 2001; 57-62.
  24. Rezaei H, Ashrafihelan J, Nematollahi A, Mostafavi E. The prevalence of *Linguatula serrata* nymphs in goats slaughtered in Tabriz, Iran. *J Parasit Dis.* 2012; 36: 200-2. <https://doi.org/10.1007/s12639-012-0104-5>
  25. Farshchi S, Alikhani MY, Choresh KS, Khaledi A, Farrash BRH, Choresh KS. Prevalence of *Linguatula serrata* nymphs in goats slaughtered in Mashhad slaughterhouse, Iran. *Avicenna J Clin Microbiol Infect.* 2018; 5(3): 52-4. <https://doi.org/10.34172/ajcmi.2018.10>
  26. Billinis C. Wildlife diseases that pose a risk to small ruminants and their farmers. *Small Rumin Res.* 2013; 110(2-3): 67-70. <https://doi.org/10.1016/j.smallrumres.2012.11.005>
  27. Mohammadi MA, Bamorovat M, Sharifi I, Mostafavi M, Zarandi MB, Kheirandish R, et al. *Linguatula serrata* in cattle in southeastern Iran: Epidemiological, histopathological and

- phylogenetic profile and its zoonotic importance. *Vet Parasitol Reg Stud Reports*. 2020;22:100465.  
<https://doi.org/10.1016/j.vprsr.2020.100465>
28. Islam R, Hossain MS, Alam Z, Islam A, Khan AHNA, Kabir ME, et al. *Linguatula serrata*, a food-borne zoonotic parasite, in livestock in Bangladesh: Some pathologic and epidemiologic aspects. *Vet Parasitol Reg Stud Reports*. 2018; 13: 135-40.  
<https://doi.org/10.1016/j.vprsr.2018.06.001>
29. Sudan V, Jaiswal AK, Shanker D. Infection rates of *Linguatula serrata* nymphs in mesenteric lymph nodes from water buffaloes in North India. *Vet Parasitol*. 2014; 205(1-2): 408-11.  
<https://doi.org/10.1016/j.vetpar.2014.07.025>
30. Gül A, İlhan F. Investigation of *Linguatula serrata* nymphs (Fröhlich, 1789) in hair goats slaughtered in Van meat and fish institution combine. 2009.
31. Shamsi S, Barton DP, Zhu X, Jenkins DJ. Characterisation of the tongue worm, *Linguatula serrata* (Pentastomida: Linguatulidae), in Australia. *Int J Parasitol Parasites Wildl*. 2020; 11: 149-57.  
<https://doi.org/10.1016/j.ijppaw.2020.01.010>
32. Jitea BA, Imre M, Florea T, Sîrbu CB, Luca I, Stancu A, Cireşan AC, Dărăbuş G. Characterization of the Tongue Worm, *Linguatula serrata* (Pentastomida), Identified from Hares (*Lepus europaeus*) in Romania. *Int J Mol Sci*. 2023; 24(16): 12927.  
<https://doi.org/10.3390/ijms241612927>
33. Mukarati NL, Vassilev GD, Tagwireyi WM, Tavengwa M. Occurrence, prevalence and intensity of internal parasite infections of African lions (*Panthera leo*) in enclosures at a recreation park in Zimbabwe. *J Zoo Wildl Med*. 2013;44(3):686-93.  
<http://dx.doi.org/10.1638/2012-0273R.1>
34. Raelle DA, Petrella A, Troiano P, Cafiero MA. *Linguatula serrata* (Fröhlich, 1789) in Gray Wolf (*Canis lupus*) from Italy: a neglected zoonotic parasite. *Pathogens*. 2022; 11(12): 1523.  
<https://doi.org/10.3390/pathogens11121523>
35. Rajabloo M, Razavi SM, Shayegh H, Alavi AM. Nymphal linguatulososis in Indian crested porcupines (*Hystrix indica*) in Southwest of Iran. *J Arthropod Borne Dis*. 2015; 9(1): 131.
36. Shamsi S, Zhu X, Halajian A, Barton DP. 28S rRNA sequences for *Linguatula* spp. *Parasitol Res*. 2022; 121(6): 1799-804.  
<https://doi.org/10.1007%2Fs00436-022-07507-6>
37. Shamsi S, Halajian A, Barton DP, Zhu X, Smit WJ, Roux F, et al. Occurrence and characterisation of tongue worms, *Linguatula* spp., in South Africa. *Int J Parasitol Parasites Wildl*. 2020; 11: 268-81.  
<https://doi.org/10.1016/j.ijppaw.2020.03.002>
38. Borgsteede FH, Tibben J, Cornelissen JB, Agneessens J, Gaasenbeek CP. Nematode parasites of adult dairy cattle in the Netherlands. *Vet Parasitol*. 2000; 89(4): 287-96.  
[https://doi.org/10.1016/S0304-4017\(00\)00219-3](https://doi.org/10.1016/S0304-4017(00)00219-3)