



## **Mini-Review Article**

# **Monkeypox (Mpox) re-emergence: prevalence, diagnostics, countermeasures, and its global effect**

**Mohammad Amir<sup>1</sup>, Manisha Vohra<sup>1</sup>, Ian Osoro<sup>1</sup>, Amit Sharma<sup>1\*</sup>, Ranjeet Kumar<sup>1</sup>**

1- Department of Pharmacy Practice, ISF College of Pharmacy, Moga, Punjab, India

\*Corresponding author: [choice.amit@gmail.com](mailto:choice.amit@gmail.com)

(Received 8 February 2023, Accepted 2 March 2023)

## **Abstract**

While the world is still trying to emerge from the crisis due to the COVID-19 pandemic, and all the nations are trying to nullify the repercussions caused by it; another outbreak known as the monkeypox virus (MPXV) has recommenced. Human monkeypox, a rare viral zoonosis (an infectious disease that can be transferred from non-human animals to humans), is caused by the MPXV, a member of the genus Orthopoxvirus (family Poxviridae, subfamily Chordopoxvirinae). Since eradicating smallpox globally in 1977, monkeypox has been the primary orthopoxvirus infection in humans. On July 14, 2022, the first case in India was reported in the Kollam district of Kerala. It manifests with the same symptoms as smallpox, including flu-like symptoms, fever, malaise, headache, back pain, and a characteristic rash. New medications have shown promising results, but more study is needed for the drug's efficacy in endemic settings. The monkeypox virus is a high-danger pathogen that causes a significant disease for public health. Consequently, there is a pressing need to develop surveillance capabilities that can yield valuable data for creating suitable preventative, preparedness, and response operations.

**Keywords:** Monkeypox, Smallpox, Bioweapon, Endemic

## **Introduction**

While the world is still trying to emerge from the crisis due to the COVID-19 pandemic and all the nations are trying to nullify the repercussions caused by it, another outbreak known as the monkeypox virus (MPXV) has recommenced. Human monkeypox, a rare viral zoonosis (an infectious disease that can be transferred from non-human animals to humans), is caused by the MPXV, a member of the genus Orthopoxvirus (family Poxviridae, subfamily Chordopoxvirinae). Further noteworthy members of this group include

the variola virus, the causative organism of smallpox, and the vaccinia virus, which is used in the vaccine used to treat smallpox. Less familiar members comprise cowpox virus, camelpox virus, and ectromelia virus (Weinstein et al., 2005). Although, the human monkeypox virus approximately clinically resembles smallpox, it is distinguishable from smallpox because of the presence of particular lymph node enlargement, which is prominent in most cases of monkeypox. Lymph-node enlargement appears early and has frequently been noticed at the time of onset of fever

(Fenner et al., 1988). The virus transmission in humans occurs during the handling of infected animals or by having direct contact with the lesions or body fluids of the infected animal (Weinstein et al., 2005). Since eradicating smallpox globally in 1977, monkeypox has been the primary orthopoxvirus infection in humans. As there is no specific treatment for human monkeypox, it has a potential to be used as a bioweapon (Di Giulio et al., 2004).

This article will review the present level of human monkeypox information, focusing on the disease's history, epidemiology representing its pathogenesis and clinical manifestation, diagnosis, treatment, and prevention.

### **Methods of review**

#### *Data Sources*

A literature search on PubMed, Medline, Google scholar, Embase, and the WHO website was performed from September 2022-December 2022 using the following search terms: monkeypox, endemic, virus, history, zoonotic disease, bioweapon, epidemiology, diagnosis, signs and symptoms, prevention, and treatment of monkeypox virus. A total of 58 articles were screened, out of which 25 articles were included in this review.

#### *Data Selection and Data Extraction*

All the English articles with relevant information like history, epidemiology, diagnosis, clinical manifestations, prevention, treatment of monkeypox disease, and are citable were included in this review.

#### *Data synthesis*

This article will examine the current state of knowledge about human monkeypox, focusing on the disease's history, epidemiology (pathogenesis and clinical manifestations), diagnosis, therapy, and prevention.

### **History**

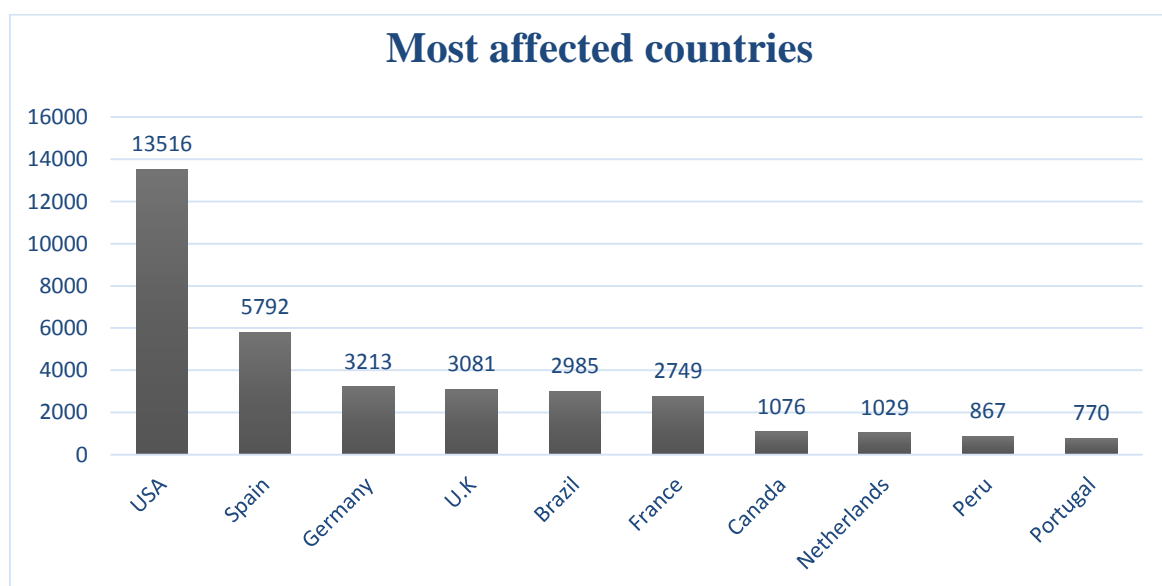
Based on the observation of lesions on infected cynomolgus macaques imported to Denmark, MPXV was identified as a member of the orthopoxvirus family in 1958 (family Poxviridae

and subfamily Chordopoxvirinae; Parker et al., 2007). In August 1970, the first human case of monkeypox was reported in Bokenda, a village in the Democratic Republic of the Congo (DRC), earlier known as the Republic of Zaire, a country situated in Central Africa (Heymann et al., 1998; Parker et al., 2007; Sklenovská and Van Ranst, 2018). A total of 4 human monkeypox cases were discovered in sub-Saharan Africa's rain forests between 1970 and 1979, with 38 of those cases reported in the DRC. The remaining patients were identified in the Central African Republic, Cameroon, Liberia, Nigeria, Sierra Leone, Gabon, and Cote d'Ivoire (World Health Organization, 1980). A nine-month-old child was admitted to the Basankusu Hospital in the Democratic Republic of the Congo on September 1, 1970, marking the first MPXV case in a human in recorded medical history (Alakunle et al., 2020). A virus similar to MPXV was discovered from the boy's ailment, which mimicked smallpox (Jezek et al., 1983; Alakunle et al., 2020). According to the Global Commission for the Certification of smallpox eradication, MPXV is the most significant orthopox virus infection in humans after the global eradication of smallpox. They also advocated that the surveillance program on MPXV should continue with giving importance to its ecology and epidemiology (World Health Organization, 1979; Sklenovská and Van Ranst, 2018). The DRC recorded the biggest monkeypox outbreak between February 1996 to February 1997. Six deaths and 71 clinical cases of monkeypox were recorded in 13 villages in Zaire between February and August 1996 (Ligon, 2004). A febrile disease outbreak accompanied by skin eruptions hit people in the mid-western United States of America between May and June 2003. Infected pet prairie dogs (*Cynomys* species) were identified in all cases imported from Ghana (Reed et al., 2004). On July 14, 2022, the first case in India was reported in the Kollam district of Kerala. A total of 10 cases of human monkeypox virus have been reported in India, of which five cases were from Delhi and the rest from Kerala.

#### 4. Epidemiology

Since humans contracted the virus through close contact with sick animals, the spread of monkeypox in sub-Saharan Africa is thought to have occurred thousands of times. According to some studies, it was speculated that the source of MPXV was likely from a rodent that was a secondary inhabitant of Central African forests (Weinstein et al., 2005). In August of 1970, the first human case of Monkeypox was reported in Bokenda, a village in the Democratic Republic of the Congo (DRC). A sample from a 9-month-old kid, who was admitted as a possible smallpox case, was forwarded to the WHO Smallpox Reference Centre (Moscow), where viral isolation revealed that it was MPXV. Additionally, it was noted that the infant was the only member of his family, who had not received a smallpox vaccination (Sklenovská and Van Ranst, 2018). Six African nations—the Democratic Republic of the Congo (DRC), Cameroon, Cote d'Ivoire, Nigeria, Liberia, and Sierra Leone—reported a total of 48 confirmed and probable cases of monkeypox during the 1970s, with the majority of cases occurring in the DRC ( $n = 38$ ). In the DRC, there was a 9-fold increase in confirmed and probable monkeypox cases between the 1980s and the 1970s ( $n = 343$ ).

In addition, 14 other cases were spread among four other African nations. In the 1990s, the cases in the DRC increased to 511, and 9 cases in Gabon were also reported. Monkeypox is most prevalent in the DRC, and no other nation has continuously reported incidences over the past five decades. Recently, an additional 4,594 suspected cases of the DRC were recorded between January and September 2020 (Bunge et al., 2022). A US outbreak of 47 confirmed or probable cases of monkeypox occurred in 2003 after exposure to infected pet prairie dogs, which had acquired the virus from affected exotic animals imported from Ghana. Before this incident, monkeypox had not previously been recorded outside of Africa (Huhn et al., 2005). According to surveillance data, monkeypox cases in the DRC surged from 0.64/100,000 in 2001 to 2.82/100,000 in 2013 (Hoff et al., 2017; Bunge et al., 2022). In most outbreaks of two or more cases and reports of a single case, males made up more than 50% of patients. Furthermore, cases outside of Africa were more prevalent among men and mostly involved adults (Hoff et al., 2017; Vaughan et al., 2018; Frez et al., 2019; Vaughan et al., 2020). Therefore, all countries' estimated case fatality rate (CFR) was 8.7% (Hoff et al., 2017). Therefore, the top 10 countries according to the confirmed cases are given in Figure 1.



**Fig. 1.** Top 10 countries according to the confirmed cases

### **Pathogenesis**

MPXV is a double-stranded DNA virus. It is one of the most lethal members of the Orthopoxvirus genus (Poxviridae family). The MPXV species is categorized into the West African clade and the Congo Basin clade. With African rodents serving as its reservoirs, MPXV is a virus affecting various mammalian species, including squirrels, mice, monkeys, and dogs. However, it has occasionally affected humans in local epidemics (Afshar et al., 2022). The route of MPXV transmission from animals to people and the specific animal host reservoir for monkeypox are yet unknown. A hospital-acquired outbreak in the Central African Republic may be explained by aerosol transmission, which has been found to occur in animals. Humans hunt tiny mammals (bushmeat) to obtain protein-rich food due to poverty and ongoing civil instability, which exposes them to more wild rodents that may spread monkeypox. Although the exact mechanism is still unknown, it is hypothesized that primary animal-to-human infection occurs through direct (bite or scratch) or indirect contact when handling animals infected with monkeypox. It is considered that the virus enters the body through ruptures in the skin, the respiratory system, or the mucous membranes. Secondary human-to-human transmission is thought to occur often and most likely through contact with large respiratory droplets, body fluids, lesion material, contaminated surfaces, or other materials like clothing or bedding (Petersen et al., 2019). The emergence of MPXV strains that are well adapted to humans could have disastrous worldwide repercussions. The potential for minor genetic alterations to facilitate adaptation to a human host is greatest for viruses with moderate transmission rates, like MPXV. Travelers' capacity to transfer MPXV efficiently and quickly to new areas may be increased by this feature (Kugelman et al., 2014).

### **Clinical manifestation**

Most cases of the clinical manifestation of human monkeypox in children and adolescents were discovered in the central and west African regions. The ailment was described as a viral prodrome fever with chills, headache, muscle pain, and backache lasting for one to three days. A maculopapular exanthematous eruption then appeared following it. Over two to three weeks, the rash changed from being primarily monomorphic with a centrifugal distribution to becoming vesicular, pustular, and producing crusts (Pal et al., 2017). The monkeypox virus can induce a disease that is clinically similar to smallpox. However, it is less contagious and has minor symptoms. The incubation period ranges from 4 to 20 days, with a mean of 12 days.

Fever may be the first sign of the prodrome or pre-eruptive stage, which lasts for 1-10 days, and body temperature rises to 40.5 degrees. Chills, heavy sweating, an intense headache, backache, muscle aches, lethargy, anorexia, prostration, pharyngitis, shortness of breath, and cough may frequently accompany the febrile sickness. In most cases, lymphadenopathy might emerge within 2–3 days after the fever. Most infected persons experience a rash within 1–10 days following the commencement of the fever. The rash usually begins on the face before spreading to other body parts. It may last for 2-4 weeks before all lesions have crusted over. According to a prior study, immunoglobulin M (IgM)-associated encephalitis was found in the cerebrospinal fluid (Sejvar et al., 2004). In the exanthematous period, lesions form synchronously during 14–21 days within body region, similar to how smallpox lesions develop. The lesions do not exhibit a prominent centrifugal dispersion, unlike smallpox. The head, face, trunk, extremities, and lesions advance from macules to papules to vesicles and pustules. Lesions can be observed on the palms and soles and develop in covered and uncovered regions. Pain is rare, and when it does occur, it generally indicates a subsequent bacterial infection. There might be necrosis, petechiae, and ulceration as features, as

well as pruritus, can also occur—patients who have already received a smallpox vaccination experience a milder form of the infection. Children might develop non-specific, erythematous papules ranging from 1 to 5 mm and simulate reactions to insect bites. The lesions of monkeypox must be differentiated from those of smallpox and chickenpox, as only chickenpox remains because smallpox was globally eradicated almost 45 years ago (Pal et al., 2017).

## Diagnosis

### *Genetic methods*

Real-time PCR (RT-PCR) or PCR is recommended for this test, and it is advised to perform it at a Biosafety Level three facility. The RT-PCR using the conserved portions of the extracellular-envelope protein gene (B6R), DNA polymerase gene, which is E9L, allows for the routine identification of MPXV DNA from clinical and veterinary materials as well as from MPXV-infected cell cultures. MPXV DNA can also be identified by the restriction length fragment polymorphism (RFLP) of PCR-amplified genes or gene fragments. However, RFLP is a tedious process and involves viral culture. Since enzyme digestion and gel electrophoresis are also required for RFLP of PCR products, this method would not be appropriate in a clinical context where speed, accuracy, and the test's specificity are critical requirements. Although RT-PCR is still the primary way to routinely detect MPXV, field genome sequencing technologies, such as the Oxford Nanopore MinION, must be used in association with it to provide significant virus genomic data, which are essential for evidence-based epidemiological interventions (Alakunle et al., 2020).

### *Electron Microscopy*

Under an electron microscope, MPXV has an intracytoplasmic brick-like shape with lateral bodies and a central core that is between 200 and 300 nm in size. Unfortunately, orthopoxvirus species cannot be distinguished morphologically. Hence this method cannot provide a conclusive diagnosis, but it does give a

hint that the virus is a component of the Poxviridae family (Alakunle et al., 2020).

### *Immunological methods*

IgG and IgM antibodies are measured using the enzyme-linked immunosorbent test (ELISA) for the immunological approach. Both T-cell responses and antiviral antibodies are known to increase early at the beginning of an illness. However, IgM and IgG are found in the serum five and more than eight days after the commencement of the rash, respectively.

### *Phenotypic models*

Other methods include the phenotypic method, which is based on clinical diagnosis. The incubation period of MPXV is around 4 and 21 days. It is preceded by a prodromal illness that consists of various symptoms such as lymph node enlargement, myalgia, severe asthenia, pharyngitis, drenching sweats, lethargy, and other typical symptoms such as fever and headache.

## Treatment and prevention

According to studies, the smallpox vaccine provides cross-protection against other Orthopoxvirus (OPV) species, including MPXV. The statistics that are now available show that 90% of the cases that have been discovered are susceptible to OPV infection, with many of them having been born after the smallpox eradication program's termination. It was found that people, who had previously received the smallpox vaccine had 85% protection against MPXV (Alakunle et al., 2020). Dryvax® was one of the well-known vaccines administered in the global smallpox eradication campaign. However, recipients experienced alarmingly high rates of cardiac problems, and when given in immunocompromised patients, severe reactions were reported. During the 2003 USA MPXV endemic, the Centers for Disease Control and Prevention (CDC) advocated smallpox vaccination (ACAM2000™, a live attenuated vaccine from Dryvax®), a second-generation vaccine that lowered symptoms but it did not prevent infection. A third-generation live attenuated vaccine, modified vaccinia Ankara (MVA), namely

Imvamune, was also recommended by CDC. ACAM2000™ has similar immunogenicity to Dryvax®, but unfortunately, it often results in cardiac adverse effects, and Imvamune also performed poorly as compared with ACAM2000™ in immunocompromised patients. Due to the limitations of the smallpox vaccines, the development of alternative treatments, including immunoglobulin and antiviral medicines, is crucial to avoiding severe or fatal OPXV infection in immunocompromised patients (Brown and Leggat, 2016). An animal model was used in a clinical trial for Tecovirimat (ST-246 or TPOXX®), a 4-trifluoromethylphenol derivative, with FDA approval.

By preventing the release of the intracellular virus from the cell, the drug has demonstrated its efficacy in treating infected animals. The human clinical trial using Tecovirimat indicated that the medication was tolerable and safe. However, the CDC report states that there is insufficient information on its efficacy in treating human MPX patients. Similar results were seen in animal and in vitro investigations utilizing Brincidofovir and Cidofovir (CMX001 or hexadecyloxypropyl-cidofovir). These two medications—an acyclic nucleoside phosphate and a liquid cidofovir conjugate—inhibit the viral DNA polymerase. Brincidofovir had a wider selectivity index, which was at least 25 times greater than cidofovir's due to its better efficacy, , albeit it had higher cellular toxicity and superior antiviral activity than cidofovir against VARV, MPXV, VACV, and CPXV in vitro (Alakunle et al., 2020). Other compounds have shown anti-poxvirus activity in vitro or in a range of small laboratory animals. Still additional investigation is needed, especially in non-human primates, before a drug approved to treat human monkeypox infections is available.

### Conclusion

In conclusion, an infection with the monkeypox virus is relatively uncommon and typically self-limiting. However, the monkeypox virus can spread to various regions due to rising globalization and cross-border animal mobility.

The infection is a typical zoonosis, unlike smallpox, which most cases result from exposure to an infected animal. Since the disease's symptoms in humans can be nearly identical to those associated with smallpox, chickenpox, or other sources of vesiculopustular rash, quick and accurate laboratory diagnoses are crucial for managing an outbreak. Monkeypox has expanded throughout West Africa and several other nations over the past ten years. Its potential for future regional and global proliferation is still a genuine concern. Monkeypox's pathogenesis, epidemiology, and clinical manifestation are still poorly known from the public health perspective. Due to the discontinuation of smallpox vaccinations, a significant percentage of the population is now unable to defend itself against monkeypox. Despite the low potential of this disease to be used as a bioweapon, the possibility of biological warfare and bioterrorism cannot be completely ruled out due to modern molecular biological advances.

### Acknowledgments

We thank ISF College of Pharmacy, Moga, Punjab, for their constant support and guidance.

### Conflict of Interest Statement:

The authors have declared that no competing interests exist.

### Ethical approval

Not Applicable.

### References

- Afshar Z.M., Rostami H.N., Hosseinzadeh R., Janbakhsh A., Pirzaman A.T., Babazadeh A., Aryanian Z., Sio T.T., Barary M. & Ebrahimpour S. The reemergence of monkeypox as a new potential health challenge: a critical review. *Authorea Preprints*, 2022.
- Brown K. & Leggat P.A. Human monkeypox: current state of knowledge and implications for the future. *Tropical Medicine and Infectious Disease*, 2016, 1(1), 8.
- Bunge E.M., Hoet B., Chen L., Lienert F., Weidenthaler H., Baer L.R. & Steffen R.

- The changing epidemiology of human monkeypox-A potential threat? A systematic review. *PLoS Neglected Tropical Diseases*, 2022, 16(2), e0010141.
- Di Giulio D.B. & Eckburg P.B. Human monkeypox: an emerging zoonosis. *The Lancet Infectious Diseases*, 2004, 4(1), 15-25.
- Emmanuel A., UgoMoens G.N. & Okeke M.I. Monkeypox Virus in Nigeria: Infection Biology. *Epidemiology and Evolution. Viruses*, 2020, 12, 1257.
- Erez N., Achdout H., Milrot E., Schwartz Y., Wiener-Well Y., Paran N., Politi B., Tamir H., Israely T. & Weiss S. Diagnosis of imported monkeypox, Israel, 2018. *Emerging Infectious Diseases*, 2019, 25(5), 980.
- Fenner F., Henderson D., Arita I., Jezek Z. & Ladnyi I. Human monkeypox and other poxvirus infections of man. *Smallpox and its Eradication. Geneva, Switzerland: World Health Organization*, 1988, 1287-320.
- Heymann D.L., Szczeniowski M. & Esteves K. Re-emergence of monkeypox in Africa: a review of the past six years. *British Medical Bulletin*, 1998, 54(3), 693-702.
- Hoff N.A., Doshi R.H., Colwell B., Kebela-Illunga B., Mukadi P., Mossoko M., Muyembe-Tamfum J.-J., Okitolonda-Wemakoy E., Lloyd-Smith J. & Rimoin A.W. Evolution of a disease surveillance system: an increase in reporting of human monkeypox disease in the Democratic Republic of the Congo, 2001–2013. *International Journal of Tropical Disease & Health*, 2017, 25(2).
- Huhn G.D., Bauer A.M., Yorita K., Graham M.B., Sejvar J., Likos A., Damon I.K., Reynolds M.G. & Kuehnert M.J. Clinical characteristics of human monkeypox, and risk factors for severe disease. *Clinical Infectious Diseases*, 2005, 41(12), 1742-51.
- Jezek Z., Gromyko A. & Szczeniowski M. Human monkeypox. *Journal of Hygiene, Epidemiology, Microbiology, and Immunology*, 1983, 27(1), 13-28.
- Kugelman J.R., Johnston S.C., Mulembakani P.M., Kitalu N., Lee M.S., Koroleva G., McCarthy S.E., Gestole M.C., Wolfe N.D. & Fair J.N. Genomic variability of monkeypox virus among humans, Democratic Republic of the Congo. *Emerging Infectious Diseases*, 2014, 20(2), 232.
- Ligon B.L. Monkeypox: a review of the history and emergence in the Western hemisphere. In: *Seminars in pediatric infectious diseases*, 2004 p. pp. 280-87.
- Pal M., Mengstie F. & Kandi V. Epidemiology, diagnosis, and control of monkeypox disease: a comprehensive review. *American Journal of Infectious Diseases and Microbiology*, 2017, 5(2), 94-99.
- Parker S., Nuara A., Buller R.M.L. & Schultz D.A. Human monkeypox: an emerging zoonotic disease, 2007.
- Petersen E., Kantele A., Koopmans M., Asogun D., Yinka-Ogunleye A., Ihekweazu C. & Zumla A. Human monkeypox: epidemiologic and clinical characteristics, diagnosis, and prevention. *Infectious Disease and Clinics*, 2019, 33(4), 1027-43.
- Reed K.D., Melski J.W., Graham M.B., Regnery R.L., Sotir M.J., Wegner M.V., Kazmierczak J.J., Stratman E.J., Li Y. & Fairley J.A. The detection of monkeypox in humans in the Western Hemisphere. *New England Journal of Medicine*, 2004, 350(4), 342-50.
- Sejvar J.J., Chowdary Y., Schomogyi M., Stevens J., Patel J., Karem K., Fischer M., Kuehnert M.J., Zaki S.R. & Paddock C.D. Human monkeypox infection: a family cluster in the midwestern United States. *The Journal of Infectious Diseases*, 2004, 190(10), 1833-40.
- Sklenovská N. & Van Ranst M. Emergence of monkeypox as the most important orthopoxvirus infection in humans. *Frontiers in Public Health*, 2018, 6, 241.
- Vaughan A., Aarons E., Astbury J., Balasegaram S., Beadsworth M., Beck C.R., Chand M., O'connor C., Dunning J. & Ghebrehewet S. Two cases of monkeypox imported to the United Kingdom, September 2018. *Eurosurveillance*, 2018, 23(38), 1800509.
- Vaughan A., Aarons E., Astbury J., Brooks T., Chand M., Flegg P., Hardman A., Harper N., Jarvis R. & Mawdsley S. Human-to-human transmission of monkeypox virus, United Kingdom, October 2018. *Emerging Infectious Diseases*, 2020, 26(4), 782.

Weinstein R.A., Nalca A., Rimoin A.W., Bavari S. & Whitehouse C.A. Reemergence of monkeypox: prevalence, diagnostics, and countermeasures. *Clinical Infectious Diseases*, 2005, 41(12), 1765-71.

---